EurAsian Journal of Oral and Maxillofacial Surgery
Official Publication of AÇBİD
(Association of Oral and Maxillofacial Surgery Society)

November 2022 Volume 1 Number 5
e-ISSN: 2687-5497

RESEARCH ARTICLE

CASE REPORTS

EurAsian Journal of Oral and Maxillofacial Surgery
Official publication of AÇBİD (Association of Oral and Maxillofacial Surgery Society)

e-ISSN: 2687-5497

EurAsian Journal of Oral and Maxillofacial Surgery
Official publication of AÇBİD
(Association of Oral and Maxillofacial Surgery Society)

EurAsian Journal of Oral and Maxillofacial Surgery
Official publication of AÇBİD (Association of Oral and Maxillofacial Surgery Society)

RESEARCH ARTICLE

Investigation of TNF-α and NF-κB Levels in Masseter Muscle of Rats with High Fructose Corn Syrup-induced Metabolic Syndrome

Ömer EKİCİ, DDS,PhD [1], **Mehmet Bilgehan PEKTAŞ,** Assoc. Prof.[2]
[1] Department of Oral and Maxillofacial Surgery, Faculty of Dentistry, Afyonkarahisar Health Sciences University, 03200, Afyonkarahisar, Türkiye.
[2] Department of Medical Pharmacology, Faculty of Medicine, Afyonkarahisar Health Sciences University, 03200, Afyonkarahisar, Türkiye.

ABSTRACT

Objective
In recent years, especially due to excessive sugar consumption, metabolic Syndrome (MetS) has become increasingly common in the world and in Turkey. The aim of the study was to investigate the inflammatory effects of high fructose corn syrup (HFCS) intake on the masseter muscle of young rats.

Materials and methods
Sixteen 3-week-old male Wistar rats were randomly split into two groups: control and HFCS. Animals were given HFCS in the form of 20% solutions in drinking water. Animals were sacrificed in the eighth week. Right masseter muscle was isolated for immunohistochemical and histopathological examination, and left masseter muscle was isolated for gene expression analysis.

Results
Both ELISA and real-time polymerase chain reaction (rt-PCR) measurements revealed that the HFCS group had significantly higher TNF-a and NF-kB levels than the control group ($p < 0.05$). Additionally, when comparing the HFCS group to the control group, a higher degree of lymphocyte infiltration was seen.

Conclusion
According to study results, young rats' masseter muscle tissue had significantly higher levels of TNF- and NF-B due to fructose-induced MetS. These findings suggest that MetS, through increased inflammation, can cause masseter muscle dysfunction, injury, fatigue, and pain.

Keywords: Metabolic syndrome, masseter muscle, inflammation, TNF-a, NF-κB.

INTRODUCTION

Metabolic Syndrome (MetS) is a medical condition defined by the presence of at least three of the following symptoms: central obesity, hypertension, hyperglycemia, high triglycerides, and low high-density lipoprotein (HDL) cholesterol.[1] MetS, a multifactorial disease, increases the risk of other diseases such as cardiovascular disease, non-alcoholic fatty liver disease, type 2 diabetes and cancer. The prevalence of MetS is increasing all over the world, especially in developed countries. In the USA, 15% of people obtain 25% of their daily energy requirement from sugar. It has been reported that the consumption of high-fructose corn syrup is 30-35 kg per person per year in the USA, more than 50% of the total sugar.[2] Many Mets animal models are created by high-carbohydrate or high-fat diets.[3] High-fructose diets, in particular, have been used successfully in animal models to develop the MetS model.[4]

Tumor Necrosis Factor α (TNF-α) is one of the main cytokines involved in inflammatory and immune processes. TNF-α also plays a key role in inflammation and cytotoxicity by interacting with cells or acting in a pleiotropic manner, increasing inflammation in different cell types and tissues. The Nuclear Factor Kappa B (NF-κB) is an important mediator of inflammatory responses and regulates many aspects of innate or acquired immune functions.NF- κB regulates inflammation by inducing the expression of several pro-inflammatory genes,

Corresponding Author: Ömer EKİCİ, DDS, PhD
Address: Afyonkarahisar Health Sciences University, Dentistry Faculty, Department of Oral and Maxillofacial Surgery, İnönü Caddesi, Afyon, Türkiye
Phone: +90(507) 217 92 75
E-mail: dromerekici@hotmail.com ORCİD: 0000-0002-7902-9601

including those encoding cytokines and chemokines. TNF-α and NF-κB activation thus play a role in the pathogenesis of many inflammatory diseases.

Masticatory muscles are crucial to human health, especially food consumption and chewing, through the stomatognathic system.[5] Masticatory muscles have been studied for structural changes in muscle type composition and/or muscle size as a result of eating habits, lifestyle, diet, and psychological or physiological stress. Masticatory muscles have been studied for structural changes in muscle type composition and/or muscle size as a result of eating habits, lifestyle, diet, and psychological or physiological stress.[6] Muscle weakness and reduced muscle mass have been linked to insulin resistance, glucose intolerance, and type 2 diabetes mellitus in some studies.[7] It has been previously reported that oxidative stress intensifies in the skeletal muscles of patients and animals with MetS.[8] Reid et al.[9] demonstrated in vitro that increased oxidative stress was linked to the onset of the weakness/fatigue process in the rat diaphragm muscle. In the literature, previous studies have been conducted on the antioxidant effects of metabolic syndrome in masseter muscle tissue.[10] However, as far as we know, there is no study in the literature examining the inflammatory effects of metS in masseter muscle tissue and investigating inflammatory cytokine expressions. This study aimed to explain the role and possible mechanisms of MetS in the formation of inflammation in masseter muscle tissue.

MATERIAL AND METHODS

Study Design

An animal experiment model was designed using 3-week-old male Wistar rats to examine the effect of MetS induced by HFCS. The research was approved by Afyon Kocatepe University Experimental Animals Local Ethics Committee (dated 11.05.2019 and number 49533702/160). This study was supported by Afyonkarahisar Health Sciences University Scientific Research Projects Commission under grant number (19.CAREER. 016).

Animals

Four-week-old male, average weight of 100 g, 16 Wistar Albino rats were taken from Afyon Kocatape University Experimental Animals Center. Wistar rats, 1-month-old weighing approximately 100 g, were substituted under 12 hours light and 12 hours dark. It was placed in temperature (20-22°C) and humidity-controlled rooms with free access to standard feed and water. After a one-week accommodation period, the animals were divided into 2 different groups. The body weights of the animals at the beginning and during the process, the amount of feed consumed and the amount of liquid they drink were recorded with weekly measurements.

A 20% (w/v) solution of HFCS (55% fructose) in drinking water was prepared twice a week and stored at +4 °C. It was added to the drinkers by shaking before giving to the animals. The animals were given standard feed (62% carbohydrates, 23% protein, 4% fat, 7% cellulose, standard vitamins and salt mixture), drinking water and drinking water containing fructose (20%). HFCS dose and duration were determined by preliminary experiments. No feed or fluid restriction was applied to the rats in the study. The feed and fluid needs of the animals were regularly monitored every day. Room ventilation and other parameters were kept under constant control.

Experimental groups

In the study, experimental animals were randomly divided into 2 groups as follows:

1. Control group: The animals were given drinking water and standard feed for eight weeks.
2. HFCS group: The animals were given drinking water, standard feed and 20% fructose corn syrup for eight weeks.

Blood glucose levels, plasma lipid, insulin, aspartate aminotransferase (AST), and alanine aminotransferase (ALT) levels were measured from the weekly blood of the animals. The weights of animals were weighed. During the study period, no loss was experienced in the experimental animals and no unexpected side effects were observed. The MetS model was established in the fourth week of the experiment and animals were sacrificed with ketamine (100 mg/kg) and xylazine (10 mg/kg) in the eighth week. Masseter muscle tissue was removed from both sides (Figure 1). The right masseter was fixed in 10 % neutral formalin for histological analysis, and the left side was stored in RNA later (Ambion Inc., Austin, TX, USA) for gene expression analysis.

Figure 1. Example of masseter muscle tissue

Measurement of weight, feed consumption, fluid and calorie intake, and some metabolic parameters in blood samples

The blood glucose level was measured in blood samples taken from the tail at the end of the experiment using a glucose meter (Accutrend® Plus). The measurements were repeated at least 3 times and the averages were taken. 4 cc blood samples taken intracardiac were centrifuged at 2200 rpm for 30 minutes and the liquid part was separated. The separated plasma was taken with a pasteur pipette, put into Eppendorf tubes and stored frozen at -85°C. Parameters measured in plasma samples were determined using appropriate enzymatic analysis kits and/or ELISA kits.

Immunohistochemical staining

For histochemical staining, 5 µm thick sections were taken from paraffin-embedded masseter muscle tissue. After deparaffinization, samples were stained with Hematoxylin-Eosin (HE) using standard protocols and examined by light microscopy (Nikon, Eclipse E600, Tokyo, Japan).

Determination of gene expressions by a real-time polymerase chain reaction(rt-PCR)

Total RNAs were isolated from masseter muscle tissues using the RNeasy total RNA isolation kit (Qiagen, Venlo, The Netherlands) as described in the manufacturer's protocol. Gene expressions were determined by mixing 1 µl cDNA, 5 µl 2X SYBR Green Master mix (Fast Start Universal SYBR Green Master Mix, Roche, Basel, Switzerland) and primer pairs at final concentrations of 0.5 µM in a total volume. 10 mL quantitative real-time PCR (LightCycler480 II, Roche, Basel, Switzerland) reactions were performed in triplicate and the specificity of the PCR products was verified using melt analysis. Relative expression of genes relative to internal control; GAPDH was calculated with the advanced relative measurement tool with efficiency correction provided by the LightCyclerVR 480 SW 1.5.1 software.

Statistical analysis

Results were reported as mean ± standard error mean. Real Time-PCR results were given as % change compared to the control group. All data were analyzed in the GraphpadPrism 6.02 statistical software program. Differences between groups were evaluated with Student's t-test or Mann-Whitney U test. A p-value of <0.05 was considered statistically significant.

RESULTS

Evaluation of metabolic syndrome parameters

The weight, feed consumption, and fluid intake of the experimental animals were monitored weekly during the feeding period. Calorie intake was calculated from the data obtained and given in Table 1.

Table 1. Weight, feed intake and metabolic parameters measured in plasma in groups

Groups	Control	HFCS
Terminal body weight (g)	291±5	365±9 *
Omentum weight/body weight (%)	0,66±0,1	1,72±0,12 *
Foodintake (g/day)	25,5±1,2	14,4±0,9 *
Liquid intake (ml/100 g bw)	16,1±2,1	13,2±1,8
Total caloricintake (kcal)	89,4±1,2	77,5±3,4 *
Glucose (mg/dL)	73±2,9	106±4 *
Insulin (ng/mL)	0,62±0,05	1,95±0,05 *
Triglyceride (mg/dL)	109±2,8	179±1 *
VLDL (mg/dl)	21,8±0,6	36±0,2 *
Cholesterol (mg/dl)	58,5±3,1	67,1±3,1 *
Fructose (µmol/L)	144±3	159±7 *
Urea (mg/dL)	52,9±3,7	64,4±1,2 *
Creatinine (mg/dL)	0,48±0,03	0,57±0,04 *
Sodium (mmol/L)	144±1,2	145±0,8
Potassium (mmol/L)	46,6±3,9	41,4±2,6
Total Protein (g/dL)	6,51±0,24	6,64±0,11
Uricacid (mg/dL)	0,98±0,1	2,6±0,08 *
ALT(IU/L)	39,6±3,3	70,6±7,4 *
AST (IU/L)	99±7,7	140±15,9 *
Calcium (mg/dL)	0,22±0,01	0,21±0,03
Iron (µg/dL)	64,3±5,4	60,2±5,4
T4 (ng/dL)	1,86±0,17	1,65±0,14
T3 (pg/dL)	2,26±0,15	2,18±0,27
Estradiol (pg/ml)	10,7±0,9	12,9±0,9 *
Total testosterone (ng/ml)	2,82±0,29	2,81±0,19

In the study, it was observed that metabolic syndrome parameters were successfully formed in the HFCS group. When Table 1 is examined, it is seen that the body weights of the rats in the HFCS group are significantly higher than the rats in the control group. In addition, blood glucose, insulin, triglyceride, VLDL, cholesterol, fructose, urea, creatinine, uric acid, ALT, AST, and estradiol levels were significantly higher HFCS group than in the control group.

Immunohistochemical and histolopathological evaluation

NF-κB and TNF-α levels of inflammatory structures were measured using ELISA kits (Cloud-Clone Corp., USA). TNFα and NF-kB level was found to be significantly higher in the HFCS group than in the control group (Figure 2).

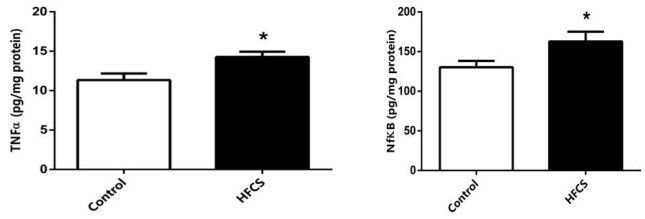

Figure 2. Comparison of the HFCS group with the control group in terms of TNF-α and NF-κB levels
* Represents significance compared to control ($p < 0.05$).

Histological examination with HE staining showed no pathological changes in the masseter muscle tissue of healthy rats, whereas the uptake of HFCS caused lymphocyte infiltration in the masseter muscle of rats (Figure 3).

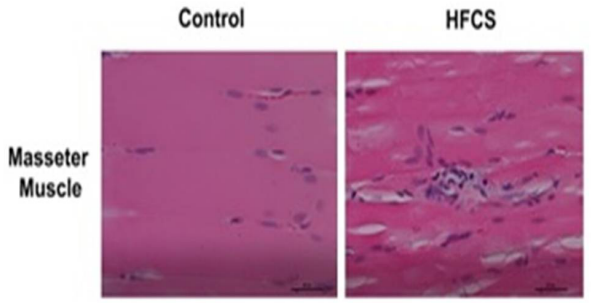

Figure 3. Histopathological features of masseter muscle tissues in the control and HFCS groups. Hematoxylin-eosin staining shows lymphocyte infiltration from both masseter muscle and gingival tissues in the HFCS groups (HE staining x 50 magnification for masseter muscle).

Evaluation of gene expressions by rt-PCR

TNF-α and NF-κB level was found to be significantly higher in the HFCS group compared to the control group (Figure 4).).

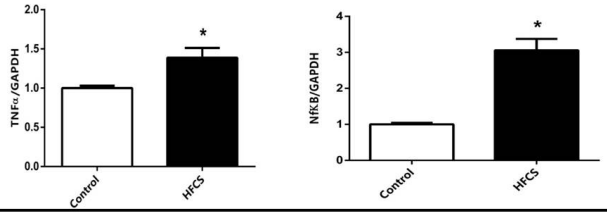

Figure 4. Comparison of the HFCS group with the control group in terms of TNF-α and NF-κB levels
* Represents significance compared to control ($p < 0.05$).

DISCUSSION

HFCS is increasingly being used to replace other caloric sweeteners, first in beverages and more recently, in thousands of other processed and packaged foods. Even though it has the same caloric value, HFCS is known to cause more harmful effects on the body than other sugars due to its high fructose content.[11] Experimental studies have shown that HFCS consumption causes many pathologies such as metabolic syndrome[12], diabetes[13], oxidative stress[14] and inflammation[15]. In addition to hyperglycemia, systemic accumulation of advanced glycation end products (AGE) was observed in rats fed a high fructose diet.[16] It has been stated that AGEs can cause oxidative stress and inflammatory reactions associated with impaired bone cell development along with metabolic disorders.[17] The findings of this study, similar to the findings of previous studies, showed an increase in parameters (plasma glucose, cholesterol, triglyceride, insulin, AST, ALT, etc.), which are the markers of metabolic syndrome, with HFCS intake. MetS criteria, including central obesity, hyperglycemia, and dyslipidemia, were successfully induced by the HFCS diet in this study. TNF-α and NF-κB levels, one of the most important proinflammatory cytokines, in the masseter muscle tissue of rats with MetS were revealed for the first time in the literature by immunohistochemical and gene expression analysis.

In this study, sections taken from the masseter muscle tissue of both sides of rats with metabolic syndrome with HFCS were examined histologically. In the histopathological examination, inflammatory effects such as increased lymphocyte infiltration were observed in the masseter muscle tissue. In addition, TNF-α and NF-κB levels were examined in masseter muscle tissue by ELISA method and a significant increase in these parameters was observed in rats with MetS. In this study, the expression of TNF-α and NF-κB genes was also examined by rt-PCR analysis, and a significant increase in the expression of these genes was observed in rats with MetS.

Previous studies in the literature have revealed that some histopathological changes occur due to oxidative increases in masseter muscle tissue. Li et al.[18] demonstrated how oxidative stress brought on by psychological stress can result in structural and functional changes in masseter muscle cells by lowering the capacity of antioxidant enzymes. On the other hand, Aghabeigi et al. [19] demonstrated that patients with chronic facial pain had higher intra-articular and systemic free radical levels. In the presence of facial pain, superoxide

dismutase (SOD) activity decreased and reactive oxygen species (ROS) formation increased, according to Viggiano et al. [20] According to Özgöçmen et al.[21] there is a significant relationship between pain and oxidative stress in fibromyalgia. In patients with myofascial pain dysfunction, Etoz et al. [22] discovered a link between increased pain and decreased total antioxidant capacity.

It has been demonstrated that MetS causes oxidative stress in the rat masseter muscle tissue. Tukel et al.[10] reported that rats with MetS had significantly lower SOD, catalase (CAT), glutathione peroxidase (GPx) and glutathione reductase (GR) activities in the masseter muscles compared to the control group. These results show that the balance between oxidant formation and antioxidant defense in the masseter muscle is impaired in MetS. Again in this study, Na + / K + -ATPase activity in the masseter muscle in the MetS group was found to be significantly lower than the control group. Decreased ATPase activity has generally been considered to be one of the manifestations of cell damage in association with free radical formation, hypoxia, or acidic metabolites.[23] Similarly, it has been shown that a diabetes-induced decrease in Na + / K + -ATPase activity prevents contraction and endurance, and causes fatigue in skeletal muscle.[24] Masseter interleukin-6 levels were found to be significantly higher in rats exposed to a combination of occlusal intervention and chronic stress compared to the control group. Also, there was a positive and significant relationship between pain response and masseter interleukin-6 level in this study.[25]

In recent years, bruxism, temporomandibular joint dysfunction and myofascial pain have become increasingly common, especially in adolescents, due to increased anxiety and stress in daily life. Metabolic syndrome may contribute to myofascial pain by causing increased inflammation in the masticatory muscles as well as in other muscles. In this study, the inflammatory and destructive effects of metabolic syndrome on masseter muscle tissue due to HFCS consumption in young adult rats were experimentally demonstrated. The study findings suggest that metabolic syndrome findings that may occur as a result of excessive sugar consumption in children may be a predisposing factor in myofascial pain and temporomandibular joint dysfunction in addition to stress factors.

The most important limitation of this study is that only TNF-α and NF-κB pathway, which are among the most important proinflammatory cytokines, were examined in this study investigating the possible inflammatory effects of metabolic syndrome on masseter muscle tissue. In future studies, other inflammatory cytokines such as IL-1, IL-6 or anti-inflammatory cytokines in masseter muscle tissue can be investigated separately. This study is the first to investigate the inflammatory effects of HFCS-induced metabolic syndrome in masseter muscle tissue. In this study, the effects of metabolic syndrome on masseter muscle tissue in young rats were comprehensively demonstrated for the first time by histological, histochemical and gene expression analysis.

CONCLUSION

The results of the study demonstrated that fructose-derived MetS significantly raised the levels of TNF-a and NF-kB in masseter muscle tissue. A higher level of inflammatory cell infiltration was also seen in the HFCS group compared to the control group during the histological examination. These results show that HFCS-induced MetS causes increased inflammation in the masseter muscle tissue as well as in other tissues in rats. These results suggest that MetS may cause masseter muscle dysfunction, pain, weakness, fatigue, and injury through impaired antioxidant or anti-inflammatory defense. Further studies are needed to elucidate the increase in inflammation in the masseter muscle tissue due to MetS and its possible mechanisms.

ACKNOWLEDGEMENT

Source of Finance
The authors are grateful to the Afyonkarahisar Health Sciences University Research Foundation, for financial support. (Grant number: 19. Kariyer.016).

Conflict of Interest
The authors report no conflicts of interest related to this study.

Funding
This study was supported by Afyonkarahisar Health Sciences University Scientific Research Projects Commission under grant number (19.CAREER. 016).

REFERENCES

1. Alberti KGMM, Eckel RH, Grundy SM, et al. Harmonizing the metabolic syndrome: A joint interim statement of the international diabetes federation task force on epidemiology and prevention; National heart, lung, and blood institute; American heart association; World heart federation; International atherosclerosis society; And international association for the study of obesity. Circulation. 2009;120(16):1640-1645. doi:10.1161/CIRCULATIONAHA.109.192644
2. Bray GA. Energy and fructose from beverages sweetened with sugar or high-fructose corn syrup pose a health risk for some people. Adv Nutr. 2013;4(2):220-225. doi:10.3945/an.112.002816
3. Brown L, Panchal SK. Rodent models for metabolic syndrome research. J Biomed Biotechnol. 2011;2011. doi:10.1155/2011/351982
4. Felice JI, Gangoiti MV, Molinuevo MS, McCarthy AD, Cortizo AM. Effects of a metabolic syndrome induced by a fructose-rich diet on bone metabolism in rats. Metabolism. 2014;63(2):296-305. doi:10.1016/j.metabol.2013.11.002
5. Sánchez GA, Trinks PW, Richard SB, Di Croce DE, Takara D. Expression of sarcoplasmic-endoplasmic reticulum Ca-ATPase isoforms in masticatory muscles. Eur J Oral Sci. 2014;122(1):36-41. doi:10.1111/eos.12098
6. Li Q, Zhang M, Chen YJ, Wang YJ, Huang F, Liu J. Oxidative damage and HSP70 expression in masseter muscle induced by psychological stress in rats. Physiol Behav. 2011;104(3):365-372. doi:10.1016/j.physbeh.2011.04.012
7. Han DS, Yu CS, Chiang CK, et al. Serum myostatin is reduced in individuals with metabolic syndrome. PLoS One. 2014;9(9). doi:10.1371/journal.pone.0108230
8. Russell AP, Gastaldi G, Bobbioni-Harsch E, et al. Lipid peroxidation in skeletal muscle of obese as compared to endurance-trained humans: A case of good vs. bad lipids? FEBS Lett. 2003;551(1-3):104-106. doi:10.1016/S0014-5793(03)00875-5
9. Reid MB, Shoji T, Moody MR, Entman ML. Reactive oxygen in skeletal muscle. II. Extracellular release of free radicals. J Appl Physiol. 1992;73(5):1805-1809. doi:10.1152/jappl.1992.73.5.1805
10. Tükel HC, Alptekin Ö, Turan B, Delilbaşi E. Effects of metabolic syndrome on masseter muscle of male Wistar rats. Eur J Oral Sci. 2015;123(6):432-438. doi:10.1111/eos.12226
11. Bray GA, Nielsen SJ, Popkin BM. Consumption of high-fructose corn syrup in beverages may play a role in the epidemic of obesity. Am J Clin Nutr. 2004;79(4):537-543. doi:10.1093/ajcn/79.4.537
12. Babacanoglu C, Yildirim N, Sadi G, Pektas MB, Akar F. Resveratrol prevents high-fructose corn syrup-induced vascular insulin resistance and dysfunction in rats. Food Chem Toxicol. 2013;60:160-167. doi:10.1016/j.fct.2013.07.026
13. Ma X, Lin L, Yue J, et al. Suppression of ghrelin exacerbates HFCS-induced adiposity and insulin resistance. Int J Mol Sci. 2017;18(6). doi:10.3390/ijms18061302
14. Sadi G, Ergin V, Yilmaz G, et al. High-fructose corn syrup-induced hepatic dysfunction in rats: improving effect of resveratrol. Eur J Nutr. 2015;54(6):895-904. doi:10.1007/s00394-014-0765-1
15. Ma X, Lin L, Yue J, et al. Ghrelin receptor regulates HFCS-induced adipose inflammation and insulin resistance. Nutr Diabetes. 2013;3(12):e99-e99. doi:10.1038/nutd.2013.41
16. Advanced glycation end-product pentosidine accumulates in various tissues of rats with high fructose intake - PubMed. https://pubmed.ncbi.nlm.nih.gov/17298207/. Accessed April 10, 2021.
17. Advanced glycation end products affect growth and function of osteoblasts - PubMed. https://pubmed.ncbi.nlm.nih.gov/21906430/. Accessed April 10, 2021.
18. Li Q, Zhang M, Chen YJ, Wang YJ, Huang F, Liu J. Oxidative damage and HSP70 expression in masseter muscle induced by psychological stress in rats. Physiol Behav. 2011;104(3):365-372. doi:10.1016/j.physbeh.2011.04.012
19. Aghabeigi B, Haque M, Wasil M, Hodges SJ, Henderson B, Harris M. The role of oxygen free radicals in idiopathic facial pain. Br J Oral Maxillofac Surg. 1997;35(3):161-165. doi:10.1016/S0266-4356(97)90555-6
20. Viggiano A, Monda M, Viggiano A, et al. Trigeminal pain transmission requires reactive oxygen species production. Brain Res. 2005;1050(1-2):72-78. doi:10.1016/j.brainres.2005.05.021
21. Ozgocmen S, Ozyurt H, Sogut S, Akyol O, Ardicoglu O, Yildizhan H. Antioxidant status, lipid peroxidation and nitric oxide in fibromyalgia: Etiologic and therapeutic concerns. Rheumatol Int. 2006;26(7):598-603. doi:10.1007/s00296-005-0079-y
22. Etoz OA, Ataoglu H, Erel O, Celik H, Herken EN, Bayazit YA. Association of serum total antioxidant capacity and total oxidant status with pain perception in patients with myofacial pain dysfunction. Int J Neurosci. 2009;119(9):1282-1291. doi:10.1080/00207450902907482
23. Allen DG. Skeletal muscle function: Role of ionic changes in fatigue, damage and disease. Clin Exp Pharmacol Physiol. 2004;31(8):485-493. doi:10.1111/j.1440-1681.2004.04032.x
24. Kjeldsen K, Braendgaard H, Sidenius P, Larsen JS, Norgaard A. Diabetes decreases Na+-K+ pump concentration in skeletal muscles, heart ventricular muscle, and peripheral nerves of rat. Diabetes. 1987;36(7):842-848. doi:10.2337/diab.36.7.842
25. Alterations in the masseter muscle and plasma IL-6 level following experimentally induced occlusal interference and chronic stress--a study in rats - PubMed. https://pubmed.ncbi.nlm.nih.gov/22856259/. Accessed June 30, 2021.

EurAsian Journal of Oral and Maxillofacial Surgery
Official publication of AÇBİD (Association of Oral and Maxillofacial Surgery Society)

RESEARCH ARTICLE

Angular Changes in Impacted Mandibular Third Molars in Young Adults

Goknur TOPALOGLU YASAN, Research Assistant[1], **Hakan H. TUZ,** Professor[2], **H. Tolga YUKSEL,** Assistant Professor[3], **Kevser BULBUL,** DDS[4], **Mine OGUZCAN,** DDS[4], **Mina SHAHMARI,** DDS[4]

[1] Hacettepe University Faculty of Dentistry Department of Oral and Maxillofacial Surgery Ankara/ Turkey
[2] Hacettepe University Faculty of Dentistry Department of Oral and Maxillofacial Surgery Ankara/Turkey
[3] Usak University Faculty of Dentistry Department of Oral and Maxillofacial Radiology Usak/Turkey
[4] Hacettepe University Faculty of Dentistry Ankara/Turkey

ABSTRACT

Background
This retrospective study aimed to evaluate vectoral alteration of impacted mandibular third molars (IMTMs) over time in patients aged 15–32 years.

Materials and methods
Angulation values of the IMTMs of 87 patients were evaluated and compared using three different references at three different time points. Angulation values of IMTMs for each reference point at each time interval were compared. Data were analyzed using chi-squared test, Mann-Whitney U test, and Kruskal-Wallis test.

Results
A significant change ($p < 0.05$) in angulation over time (either increase or decrease) was observed in the measured IMTMs at all three reference points. However, no significant result was found in terms of the direction of this change in any group.

Conclusion
The angle between the IMTM axis and different reference points may change over time. However, estimation of the magnitude or direction of angular change does not seem to be possible.The decision to recommend extraction or retention of asymptomatic IMTM should be made by considering the patient's expectations, needs and the physician's experience.

Keywords: angle, eruption, impaction, panoramic radiograph, radiology.

INTRODUCTION

Third molars have the highest rate of impaction of all teeth [1-3].Mandibular third molars are the second most commonly impacted teeth, after maxillary third molars[4]. Impaction of third molars can occur due to lack of space around them, unfavorable changes in angulation, or a combination of these two factors. Although the etiology of third molar impaction has not been fully explained, there is a strong belief that a lack of space is the primary factor[5, 6].

Third molars should be removed when they are associated with any pathological condition such as pericoronitis, cystic lesions, tumors, dental caries, periodontitis, periapical infection, or root resorption of adjacent teeth. It has been estimated that 54% of mandibular third molars are removed prophylactically, without presenting any subjective symptoms [4, 7].

It can be hypothesized that, while erupting, the angulation of third molars does not change over time. However, it is important to know the alteration of third molar angulation and the relationship with the second molar over time, if not removed at the first diagnosis. Thus, necessity of prophylactic extraction should be determined.

The aim of this retrospective study was to evaluate vectoral alteration of impacted mandibular third molars (IMTM) over time in patients aged 15–32 years.

Corresponding Author: Goknur TOPALOGLU YASAN, Research Assistant
Address: Hacettepe University Faculty of Dentistry Department of Oral and Maxillofacial Surgery, Ankara, Türkiye
Phone: +90(530) 282 41 09
E-mail: goknurtopaloglu@gmail.com ORCİD: 0000-0002-0039-6688

MATERIALS AND METHODS

The study population consisted of 87 patients (57 female and 30 male) referred to Hacettepe University Faculty of Dentistry between 2010 and 2020. The study was approved by the Ethics Committee of Hacettepe University (GO 20/765). The patients were divided into three age groups: 16–19 years, 20–23 years, and > 23 years. Patients' panoramic radiograph records were retrieved from the archives of Hacettepe University Department of Oral and Maxillofacial Radiology and were reviewed.

In this retrospective study, a tooth was considered affected if it had not fully erupted to the assumed normal functional position in the occlusal plane.

Patients who had more than one panoramic radiograph obtained at different time points and had impacted mandibular third molars in all radiographs were included in this study. Patients with a history of unilateral or bilateral mandibular molar or premolar extractions were excluded. To evaluate the angulation of an impacted mandibular third molar, the reference regions were defined as the longitudinal axis of the second molars, mandibular occlusal plane, and the line tangent of the basis of mandible (Figures 1, 2, 3). The angle between the axis of the IMTM and each reference point was measured and recorded. Two observers performed all measurements. Observers performed measurements on two panoramic radiographs taken at different time points for each patient. The difference between the angles was measured (Figures 4A, 4B).

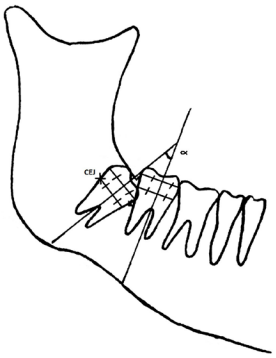

Figure 1: Angle measurement between the axis of impacted mandibular third molar and longitudinal axis of second molar.

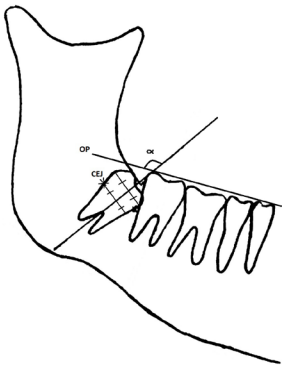

Figure 2: Angle measurement between the axis of impacted mandibular third molar and mandibular occlusal plane.

Figure 3: Angle measurement between the axis of impacted mandibular third molar and the line tangent of basis of mandible.

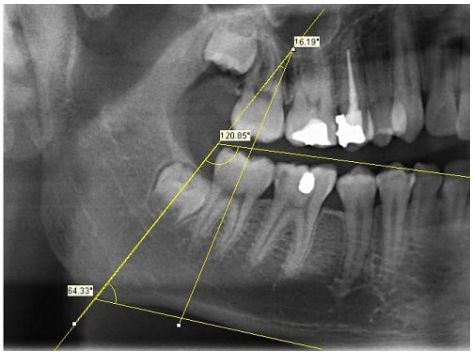

Figure 4A: Angle measurements between the axis of impacted mandibular third molar and each reference points of a 16 year old male patient.

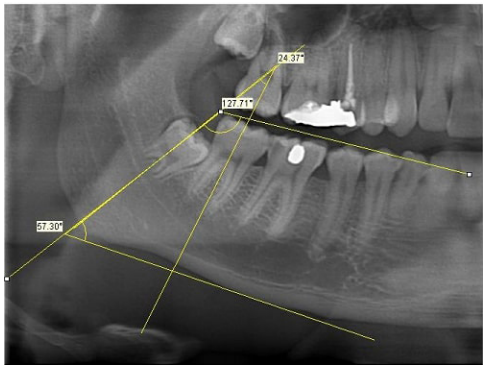

Figure 4B: Angle measurements between the axis of impacted mandibular third molar and each reference points of the same patient 2 years later.

The collected data were evaluated for correlations among age group, sex, and angle difference between the first and second measurements using SPSS Software for Windows with a confidence interval of 95%. The p-value less than 0.05 ($p < 0.05$) was considered as statistically significant. (IBM Corp. Released 2013. IBM SPSS Statistics for Windows, Version 22.0.

Armonk, NY: IBM Corp).

An intraclass correlation coefficient (ICC) was used to assess the consistency between observers. A chi-square test, Mann-Whitney U test, Kruskal-Wallis test, and Spearmen correlation coefficient were used to determine the factors affecting the change in angulation difference depending on the type of variable.

RESULTS

Of the 87 patients included in the study; 65.5 % were female and 34.5 % were male, aged 15–32 years (mean, 19.6 ± 3.2 years). No significant difference was found among age groups and between sex ($p > 0.05$).

The absolute value of angle change was found to be statistically significant ($p = 0.00$, %95 Confidence Interval) regardless of whether the change was an increase or a reduction. Both increases and reductions in the angle between the third molar axis at each reference point were observed over time. However, no significant direction of change was identified in any of the groups studied. There was no observed correlation between the primary angle measurement (greater than or less than 45°) and the magnitude of angle change over time.

ICC (Intraclass Correlation Coefficient) revealed no significant difference between the measurements of the two observers.

DISCUSSION

Limited information is available regarding the variations of the eruption pattern of third molars in individuals aged 15–32 years. The long-term sequelae of impacted third molars are still not clear [8]. Time of eruption of third molars showed considerable variation among populations ranging from 14 to 24 years [9]. The most common surgical intervention in dentistry is the extraction of third molars in young adults; most patients are over the age of 20 years [7, 10]. Although indications for the removal of symptomatic third molars are well established, a convincing case for the prophylactic removal of unerupted, asymptomatic, disease-free third molars has not yet been reported [11]. Hence, it is important to know the alteration in third molar angulation and the relationship with the second molar over time if not removed immediately. According to the American Association of Oral and Maxillofacial Surgeons (AAOMS) Third Molar Multidisciplinary Conference, it has still not been determined whether individuals who undergo extraction of impacted third molars have better outcomes when compared with patients who retain such teeth, among patients with asymptomatic, disease-free third molars [8]. Similarly, a review on the Cochrane Collaboration of the surgical removal of asymptomatic affected wisdom teeth by Mettes TG et al. (2012) concluded that "no evidence was found to support or refute prophylactic removal of asymptomatic impacted wisdom teeth in adults [12].

Age is a common factor in determining when an asymptomatic third molar should be extracted. The rationale is that early extractions are easier, less traumatic, and reduce the likelihood of complications. Age is not a predisposing factor for increased complications, but with increasing age, there is an increase in health risk factors, which influence postoperative recovery [13-16]. According to our results, no significant difference in the angulation of IMTM was found among age groups. It should also be remembered that radiographic position is not the only determinant of whether a third molar should be removed surgically. Factors such as symptoms, infection, caries, and the potential for damage to adjacent teeth and other structures must also be considered.

Studies of occlusal stability reveal that third molars in mesioangular or horizontal positions may have an impact on mandibular incisor crowding and on the stability of orthodontic treatment [2, 17, 18]. Based on this idea, prevention of late incisor crowding has also been proposed as a reason to justify the removal of impacted third molars. However, other studies report that third molars have no effect on mandibular incisor crowding [19, 20]. Hence, this idea is still controversial.

Unilateral or bilateral mandibular molar or premolar extraction has been shown to have a favorable effect on the angulation of third molars [21-23]. Therefore, patients with a history of unilateral or bilateral mandibular molar or premolar extraction were excluded from our study.

The incidence of pathologic conditions associated with impacted third molars and the need for their prophylactic removal are controversial [24].

Few studies have examined the change of angulation of affected third molars. Impacted teeth that remain static, with no change in position or angulation over time, are considered rare [25]. These changes take place over a wide time frame and the change in angulation may be positive or negative. However, some studies report that third molars improve their angulation and position relative to the occlusal plane, and become upright or fully erupt over time [12, 26, 27]. Thus, close monitoring of asymptomatic impacted third molars in young adults, instead of prophylactic removal, has been suggested.

The results of our study consistently revealed that the positions of IMTMs change over time and this change was statistically significant. Both increases and decreases in the angle between the third molar axis and each reference point were observed over time. However, no statistically significant result was found in terms of the direction of the change in any group.

CONCLUSIONS

Angulation of IMTM changed over time. However, the direction of the alteration was unpredictable. The magnitude of the alteration could not be correlated with the tooth's initial position. The angle between the third molar axis and different reference points may change over time. However, it is not possible to estimate the magnitude and direction of angular

change of third molars over time. The effect of angular change of an IMTM may also interact with anatomical structures such as the mandibular canal. A limitation of this study is that the effect of this alteration was not evaluated as a part of the measurements.

As the IMTM's position, development, and relationship with adjacent anatomic structures over time is unpredictable and varies for each individual, the decision to recommend extraction or retention of asymptomatic IMTM should be made by considering the patient's expectations and needs and the physician's experience.

ACKNOWLEDGEMENT

Source of Finance

The authors are grateful to the Afyonkarahisar Health Sciences University Research Foundation, for financial support. (Grant number: 19. Kariyer.016).

Conflict of Interest

The authors declare that there is no conflicts of interest.

Funding

This study was supported by Afyonkarahisar Health Sciences University Scientific Research Projects Commission under grant number (19.CAREER. 016).

REFERENCES

1. Dachi, S.F. and F.V. Howell, A survey of 3, 874 routine full-month radiographs. II. A study of impacted teeth. Oral Surg Oral Med Oral Pathol, 1961. 14: p. 1165-9.
2. Bishara, S.E. and G. Andreasen, Third molars: a review. Am J Orthod, 1983. 83(2): p. 131-7.
3. Grover, P.S. and L. Lorton, The incidence of unerupted permanent teeth and related clinical cases. Oral Surg Oral Med Oral Pathol, 1985. 59(4): p. 420-5.
4. Shepherd, J.P., The third molar epidemic. Br Dent J, 1993. 174(3): p. 85.
5. Silling, G., Development and eruption of the mandibular third molar and its response to orthodontic therapy. Angle Orthod, 1973. 43(3): p. 271-8.
6. Ricketts, R.M., A principle of arcial growth of the mandible. Angle Orthod, 1972. 42(4): p. 368-86.
7. Shepherd, J.P. and M. Brickley, Surgical removal of third molars. BMJ, 1994. 309(6955): p. 620-1.
8. Dodson, T.B., et al., Summary of the proceeding of the Third Molar Multidisciplinary Conference. J Oral Maxillofac Surg, 2012. 70(9 Suppl 1): p. S66-9.
9. Kruger, E., W.M. Thomson, and P. Konthasinghe, Third molar outcomes from age 18 to 26: findings from a population-based New Zealand longitudinal study. Oral Surg Oral Med Oral Pathol Oral Radiol Endod, 2001. 92(2): p. 150-5.
10. Spencer, A.J., et al., Service-mix of oral and maxillofacial surgeons in Australia and New Zealand. Int J Oral Maxillofac Surg, 1993. 22(5): p. 310-3.
11. Kandasamy, S., D.J. Rinchuse, and D.J. Rinchuse, The wisdom behind third molar extractions. Aust Dent J, 2009. 54(4): p. 284-92.
12. Mettes, T.D., et al., Surgical removal versus retention for the management of asymptomatic impacted wisdom teeth. Cochrane Database Syst Rev, 2012. 6: p. CD003879.
13. Haug, R.H., et al., The American Association of Oral and Maxillofacial Surgeons Age-Related Third Molar Study. J Oral Maxillofac Surg, 2005. 63(8): p. 1106-14.
14. Baqain, Z.H., et al., Frequency estimates and risk factors for postoperative morbidity after third molar removal: a prospective cohort study. J Oral Maxillofac Surg, 2008. 66(11): p. 2276-83.
15. Bui, C.H., E.B. Seldin, and T.B. Dodson, Types, frequencies, and risk factors for complications after third molar extraction. J Oral Maxillofac Surg, 2003. 61(12): p. 1379-89.
16. Chuang, S.K., et al., Age as a risk factor for third molar surgery complications. Journal of Oral and Maxillofacial Surgery, 2007. 65(9): p. 1685-1692.
17. Peterson, L.J., Rationale for removing impacted teeth: when to extract or not to extract. J Am Dent Assoc, 1992. 123(7): p. 198-204.
18. Alling, C.C., 3rd and G.A. Catone, Management of impacted teeth. J Oral Maxillofac Surg, 1993. 51(1 Suppl 1): p. 3-6.
19. Ades, A.G., et al., A long-term study of the relationship of third molars to changes in the mandibular dental arch. Am J Orthod Dentofacial Orthop, 1990. 97(4): p. 323-35.
20. Hasegawa, Y., et al., Influence of third molar space on angulation and dental arch crowding. Odontology, 2013. 101(1): p. 22-8.
21. Bayram, M., M. Ozer, and S. Arici, Effects of first molar extraction on third molar angulation and eruption space. Oral Surg Oral Med Oral Pathol Oral Radiol Endod, 2009. 107(2): p. e14-20.
22. Staggers, J.A., N. Germane, and W.M. Fortson, A comparison of the effects of first premolar extractions on third molar angulation. Angle Orthod, 1992. 62(2): p. 135-8.
23. Saysel, M.Y., et al., The effects of first premolar extractions on third molar angulations. Angle Orthod, 2005. 75(5): p. 719-22.
24. Song, F., et al., Prophylactic removal of impacted third molars: an assessment of published reviews. Br Dent J, 1997. 182(9): p. 339-46.
25. Phillips, C. and R.P. White, How Predictable Is the Position of Third Molars Over Time? Journal of Oral and Maxillofacial Surgery, 2012. 70(9): p. S11-S14.
26. Kandasamy, S., Evaluation and management of asymptomatic third molars: Watchful monitoring is a low-risk alternative to extraction. Am J Orthod Dentofacial Orthop, 2011. 140(1): p. 11-7.
27. von Wowern, N. and H.O. Nielsen, The fate of impacted lower third molars after the age of 20. A four-year clinical follow-up. Int J Oral Maxillofac Surg, 1989. 18(5): p. 277-80.

EurAsian Journal of Oral and Maxillofacial Surgery
Official publication of AÇBİD (Association of Oral and Maxillofacial Surgery Society)

RESEARCH ARTICLE

In The Le Fort I Osteotomy Performed Patients Effect of Cinch Sütür On The Nose Soft Tissue

Yusuf TAMER, PhD [1], **Sina UÇKAN,** Prof.[2]
[1] Başkent University,Turgut Noyan Adana Research and Training Hospital, ADANA, Türkiye.
[2] Medipol University, Türkiye.

ABSTRACT

Objective
The purpose of this study was to evaluate the effect of cinch suture to prevent enlargement in the nasal tissue of 15 patients who maxillary advancement and impaction surgery with Lefort I osteotomy.

Material and methods
This study 15 orthognathic surgery patients (9 female, 6 male) underwent maxillary advancement and impaction surgery with Lefort I were included. While the average amount of advancement of the upper jaw is 5±1.55 mm; impaction amount is 2.5±0.83 mm. The patients were seperated into two groups, cinch suture performed (cinch suture group) and cinch suture not performed (control group). Before the operation the width lateral point of nose wings alar wideness (AW) and the joint that nose wings with face on base inferior subalar wideness (SAW) was assigned. Nasolabial angle (NLA) was determined on cephalometric radiographs taken before and after surgery. The mean follow-up period of the study was 7.2±0.8 months. All datas from this study was analized by 'Statistical Packages for the Social Science' statistical programme.

Results
After orthognatic surgery a significant increased on AW point observed on both group the cinch sütüre performed and the control group. While the difference between the groups in AG was not significant (p=0.463), the difference between the groups in SAG was significant (p=0.047). NLA measurements after orthognathic surgery decreased in the cinch suture group (p=0.182) and increased in the control group (p=0.865).

Conclusion
Despite cinch suture increased observed on both AW and SAW point after Lefort 1 osteotomy. We can say that while cinch suture finded beneficial to contain the enlargement of SAW, finded insufficient for prevention of enlargement AW. In our study, no significant effect of cinch suture on NLA was found. In contrast to cinch suture the risk of enlargement nasal wings should be considered and the patient should be informed before the operation.

Key Words: Lefort I, Orthognatic Surgery, Suture Techniques

Genel anestezi komplikasyonlarının azalması, kemik fiksasyon tekniklerindeki ilerlemelerin sonucu iskeletsel bozukluğu olan ve sadece ortodontik tedaviyle düzeltilemeyen hastalarda gün geçtikce artan sayıda ortognatik cerrahi planlaması ve ameliyatı yapılmaktadır. Ortognatik cerrahi prosedüler ile üst ve alt çenenin konumları değiştirilerek iskeletsel ve yumuşak dokuda değişimler elde edilmesi amaçlanır. Ortognatik cerrahide iskeletsel değişim planlandığı gibi elde edilirken yumuşak doku değişimi planlan hareket sınırların dışında kalabilir. Bu sebeple iskeletsel kaide ve yumuşak doku hareketi arasındaki ilişkiyi anlamak, ortognatik cerrahi tedavisinin başarısı açısından son derece önemlidir.

Lefort I osteotomisi orta yüzü deformiteleri düzeltmek amacıyla amacıyla maksillayı üç boyutta hareketlendirerek çok yönlü kullanılan ve en fazla tercih edilen ortognatik cerrahi tekniktir. Lefort I osteotomisi ile maksillanın yeniden konumlandırılması iskeletsel değişime bağlı olarak burun kanatı ve tabanının genişlemesine, burun ucunun değişimine ve dudakların incelmesine yol açabilir. Burun yüzün merkezinde, yüz estetiğinin ve ifadesinin önemli bir parçasıdır. Yüzün ortasında dikkat çeken konumda bulunması nedeniyle küçük asimetri ve düzensizlikler çabuk göze çarpar. Bundan dolayı burun yapısını etkileyebilecek Lefort I cerrahisinde dikkatli olunmalıdır.

Corresponding Author: Yusuf TAMER, PhD
Address : Başkent University,Turgut Noyan Adana Research and Training Hospital, ADANA, Türkiye
Mobile : +90(536) 266 75 72
e-mail : dryusuftamer @gmail.com

Lefort I cerrahisinin burunda meydana getirdiği etkilerden biri burun tabanındaki genişlemedir. Burun tabanın genişlemesi sadece burun estetiğini olumsuz etkilemez ayrıca nazolabial sulcusun derinliğini artırarak daha yaşlı bir görüntüye sebep olur., Maksillanın ilerletme ve gömme hareketlerinde burun tabanı genişlemesi en fazla olmaktadır. Bu harekete bağlı oluşacak burun kanatının genişlemesini engellemek için cinch sütür kullanılması önerilmektedir. İlk zamanlar dudak-damak yarıklı hastalarda Millard tarafından uygulanan cinch sütür tekniği daha sonra Epker ve Collins tarafından ortognatik cerrahi hastalarında kullanmak için rapor edilmiştir.

Bu çalışmanın amacı Lefort I tekniğiyle opere ettiğimiz ve hareket vektörleri maksiller ilerletme ve gömme olan hastalarda burun yumuşak dokusunda meydana gelen genişlemeyi engellemek için uygulanan cinch sütürün etkisini değerlendirip, literatüre katkıda bulunmaktır.

GEREÇ ve YÖNTEM

Bu çalışmaya 2017-2019 yıllarında Başkent Üniversitesi Diş Hekimliği Fakültesi Ağız, Diş Çene Hastalıkları ve Cerrahisi Anabilim Dalı'nda gelişimsel anomaliye bağlı maloklüzyon nedeniyle ortodontik tedavi gören ve tedavisinde maksillaya ilerletme ile birlikte gömme cerrahisi ile aynı anda mandibulaya bilateral sagital split ramus osteotomisi (BSSRO) planlanmış ardışık 15 ortognatik cerrahi hastası (9 Kadın, 6 erkek) dahil edilmiştir. Bu çalışma, Başkent Üniversitesi Tıp ve Sağlık Bilimleri Araştırma Kurulu ve Etik Kurulu tarafından onaylanmış (Proje no: D-KA12/08) ve Başkent Üniversitesi Araştırma Fonunca desteklenmiştir. Araştırmaya

- Dudak-damak yarığı gibi konjenital bir anomali veya sendromu olanlar
- Alt ve orta yüz bölgesinde belirgin skarı olanlar
- Estetik burun ameliyatı geçirmiş olanlar
- Daha önce ortognatik cerrahi veya distraksiyon osteogenezi cerrahisi ya da maksiller vestibülü içeren geniş bir insizyon yapılmış olanlar çalışma grubuna dahil edilmemiştir.

Ortognatik cerrahi planlanan hastaların burunlarında meydana gelebilecek değişimleri tespit etmek amacıyla sağ ve sol burun kanatının en lateral noktaları arası alar genişlik (AG) ve burnun kanatının tabanda yüz ile birleştiği noktalar arası subalar genişlik (SAG) olarak belirlenmiştir (Şekil 1). Hastaların ortognatik cerrahiden hemen önce ve 6 ay geçtikten sonra alınan sefalometrik radyografilerinde nazolabilal açı (NLA) değişimini ölçmek için referans noktalar belirlenmiştir (Şekil 2). Belirlenen noktalar arasından ölçümler yapılarak değişim miktarları kaydedilmiştir. Operasyon tarihinden bir gün önce (T1) ve 6 ay (T2) sonra AG, SAG ve NLA olarak yapılan ölçümler kaydedilmiştir. Cinch sütür kullanılan hastalar 'cinch sütür' gurubu, cinch sütür kullanılmayan hastalar 'kontrol' gurubu olarak sınıflandırılmıştır.

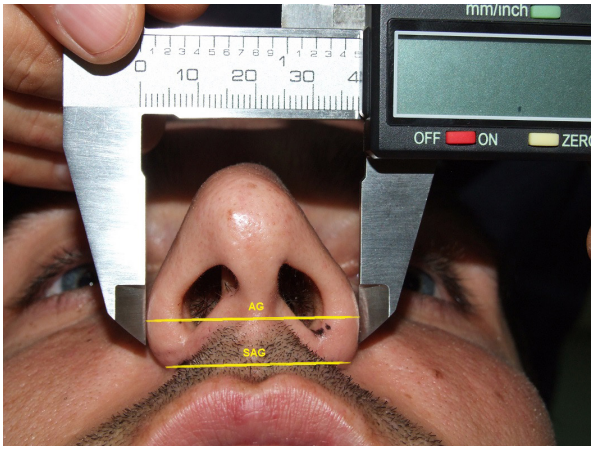

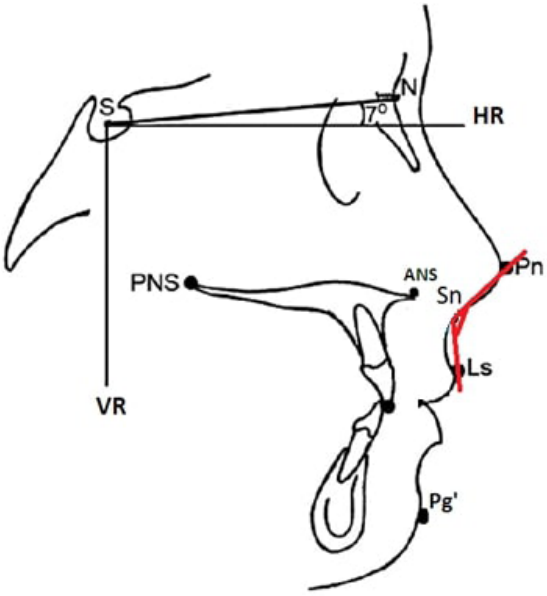

Cerrahi Yöntem

Hastalar uygun bir şekilde nazoendotrakeal olarak entübe edildikten sonra genel anestezi eşliğinde ameliyat uygulanmıştır. Lokal anestezik (Ultracain, Aventis, İstanbul Türkiye) enjeksiyonu takiben bilateral maksiller 2. premolar dişler arasında yapışık dişetinin biraz üstünden horizontal insizyon tercih edilmiştir. Subperiosteal diseksiyonla öncelikle apertura piriformisin kenarları daha sonra da infraorbital foramen gözlenmiştir. Diseksiyon arkalarda zigomatikomaksiller sütur, zigomatik buttress ve zigomanın anterioru görülecek şekilde genişletilmiş ve subperiosteal tünel diseksiyonla pterygoid proçese doğru ilerlenmiştir. Nazal mukoza, lateral nazal duvar ve tabandan diseke edilmiştir. Osteotomiye apertura piriformisin lateral yüzeyinden başlanmış, posteriora doğru pterygomaksiller bileşke doğrultusunda hat oluşturacak şekilde osteotomi tamamlanmıştır. Septal osteotom ile nazal septum ve vomer maksilladan ayrılmıştır. Küçük eğimli osteotom pterygomaksiller bileşkeye medial ve inferiora yönlenecek

şekilde yerleştirilerek osteotomiler tamamlanmıştır. Maksilla basit bir manipülasyon ile aşağı doğru kırılmış ve serbest hale getirilmiştir. Okluzal splint yardımıyla maksilla ve mandibula uygun oklüzyonda birbirine maksillomandibuler fiksasyon (MMF) ile tespit edilmiştir. Uygun pozisyonda, her iki zigomatikomaksiller buttress ile lateral nazal duvar bölgesine yerleştirilen toplam dört adet mini plak (Synthes, Solothurn, Switzerland) ile maksillar tespit sağlanmıştır. İnsizyon hattı primer olarak 3.0 vicryl sütür (Coated Vicyryl, Ethicon, Johnson & Johnson Int Belçika) ile kapatılmıştır. Hastaların hepsinde Le Fort I cerrahi işlemi sonunda insizyon hatları basit devamlı sütur kullanılarak kapatılmıştır. Basit devamlı sütüra ek bazı hastada cinch sütur ilave edilmiştir. Cinch sütür; vestibüler insizyondan ulaşılan sol ve sağ subalar tabandaki fibroareolar dokudan geçen 3-0 erimeyen (Prolen) süturün çekilerek yeterli gerginlik elde edilmesinden sonra bağlanmasıyla olur. Cinch sütürün hangisi hastaya uygulanacağı ortodontist ve cerrahın klinik tecrübe ve deneyimlerine göre, iki klinisyen tarafından karar verilmiştir. Operasyon sırasında cinch sütür ile ilgili değerlendirmeler kaydedilmiştir.

Splint çıkarılıp mandibulada sagittal split ramus osteotomisi (SSRO) planlanan hastalarada uygun teknikle mandibular osteotomi uygulanmıştır. Tüm hastalara, operasyon sırasında 1.5 mg/kg metil prednizolon (Depo-medrol, Eczacıbaşı, Türkiye) ve 1 gr sefalosporin (Cefozin, Bilim, Türkiye) yapılmıştır. Postoperatif antibiyotik, antiseptik ağız gargarası ve non-steroidal anti inflamatuar ağrı kesici reçete edilmiştir.

İstatistiksel Analiz

Çalışmadan elde edilen tüm veriler "Statistical Packages for the Social Science" (SPSS) 11.5 istatistik programı kullanılarak analiz edilmiştir. Tanımlayıcı istatistiksel analizler; frekans, yüzde, medyan (minimum-maksimum) biçiminde ifade edilmiştir. Grupların nominal değişkenler açısından farklı olup olmadığını saptamak amacıyla Fischer Exact test veya Pearson Ki-kare testi; Gruplar arası sürekli değişkenlerin Mann Whitney U test kullanılmıştır. Gruplardaki sürekli değişkenlerin önceki ile sonraki değerleri Wilcoxon Signed-rank test ile karşılaştırılmıştır. p<0,05 değeri istatistiksel olarak anlamlı olarak değerlendirilmiştir.

BULGULAR

Hasta yaş aralığı 18-29 (ortalama 24)'dur. Hastaların 14'ü Class III, 1'i Class II iskeletsel bozukluk nedeniyle opere edilmiştir. Katılanların %60'ı kadın, %40'ı erkekti. Hastaların tümü aynı ekip tarafından opere edilmiş, operasyon öncesi ve sonrası ortodontik takip ve tedavileri ise aynı ortodontist tarafından yürütülmüştür. Çalışmanın ortalama takip süresi 7,2±0,8 aydır. Hastaların hepsine çift çeneyi kapsayan cerrahi işlem uygulanmıştır. Çalışmamızda maksilladaki ortalama ileri yöndeki hareket 5 mm, yukarı yöndeki hareket 2,5 mm'dir. Maksilada ilerletme ve gömme miktarlarını gösteren grafik Şekil 3'dür. 15 hastanın 8'inde cinch sütür kullanılmış, 7'sinde kullanılmamıştır.

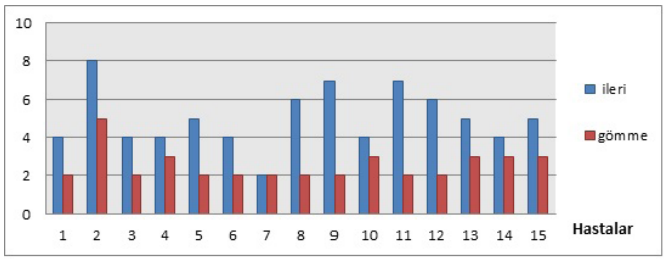

Şekil 3: Maksillanın ileri ve gömme miktarlarını gösteren grafik.

Alar Genişliğe (SA) Ait Bulgular

Ortognatik cerrahi işlem sonrası cinch sütür uygulanan grupta alar genişlikte ortalama 1,88±0,64 mm anlamlı artış gözlenmiştir (p=0,010). Kontrol grubundaki alar genişlikte 2,29±0,95 mm anlamlı artış gözlenmiştir (p=0,016).

Subalar Genişliğe (SAG) Ait Bulgular

Ortognatik cerrahi işlem sonrası cinch sütür uygulanan grupta subalar genişlikte ortalama 1,88±0,64 mm anlamlı artış gözlenmiştir (p=0,010). Kontrol gurubunda subalar genişlikte 2,57±0,53 mm anlamlı artış gözlenmiştir (p=0,015). Bu ölçümde gruplar arasındaki fark istatistiksel olarak anlamlı bulunmuştur (p=0,047) (Tablo).

Nazolabial Açı (NLA) Değişimine Ait Bulgular

Ortognatik cerrahi işlem sonrası cinch sütur uygulanan grupta NLA ölçümlerinde ortalama 4,63º±9,68º anlamlı olmayan azalma gözlenmiştir (p=0,182). Cinch sütur uygulanmayan grupta NLA ölçümünde ortalama 2,29º±8,42º anlamlı olmayan artış gözlenmiştir (p=0,865). Bu ölçümde gruplar arasındaki fark istatistiksel olarak anlamlı bulunmamıştır (p=0,081) (Tablo).

Tablo: Cinch sütur uygulanan ve uygulanmayan olguların cerrahi öncesi ve sonrası (T2-T1) AG, SAG ve NLA değerleri ve bu değerlerdeki değişimlerin karşılaştırılması.

		Cinch sütur										p†
		Uygulandı					Uygulanmadı					
		Ort	SS	Med	Min	Mak	Ort	SS	Med	Min	Mak	
AG (mm)	T1	33.88	3.09	33.50	30.00	40.00	33.43	2.37	33.00	30.00	36.00	**0.905**
	T2	35.75	2.71	35.00	32.00	41.00	35.71	2.21	36.00	32.00	38.00	**0.814**
	p††	**0.010**					**0.016**					
	T2-T1	1.88	.64	2.00	1.00	3.00	2.29	.95	2.00	1.00	4.00	**0.463**
SAG(mm)	T1	22.87	2.70	22.00	20.00	28.00	23.86	3.34	22.00	21.00	28.00	**0.680**
	T2	24.75	2.38	24.50	22.00	29.00	26.43	3.21	25.00	23.00	31.00	**0.348**
	p††	**0.010**					**0.015**					
	T2-T1	1.88	.64	2.00	1.00	3.00	2.57	.53	3.00	2.00	3.00	**0.047**
NLA (º)	T1	101.13	5.82	103.00	90.00	108.00	98.86	8.69	102.00	88.00	110.00	**0.602**
	T2	96.50	8.47	96.50	85.00	111.00	101.14	7.88	102.00	85.00	108.00	**0.294**
	p††	**0.182**					**0.865**					
	T2-T1	-4.63	9.68	-6.00	-15.00	12.00	2.29	8.42	-2.00	-4.00	20.00	**0.081**

p†: İlgili değişken için Cinch sütur uygulanan grup ile uygulanmayan grubun T1 değerlerinin, T2 değerlerinin ve değerlerde oluşan değişimlerin (T2-T1) karşılaştırılması (Mann Whitney U Testi).
p††: Cinch sütur uygulanan ve uygulanmayan grupların her biri için ilgili değişkenin T1 ile T2 değerlerinin karşılaştırılması (Wilcoxon Signed Rank Test).

TARTIŞMA

Le Fort I osteotomi esnasında yapılan subperiosteal diseksiyon kasları kolumellolabial bölgedeki insersiyolarından ayırması nedeniyle nasal bölgedeki genişleme tüm hastalarda görülmektedir.[7] Bu istenmeyen genişlemeyi kontrol altına almak için cinch sütüre uygulanması önerilmektedir. Bazı çalışma sonuçlarında cinch sütürün alar tabanın genişlemesini engellediği belirtilsede12, kimi çalışmalarda cinch sütür etkisinin beklenildiği kadar olmadığı, etkisinin sınırlı olduğu sonucunu rapor edilmiştir., Çalışmamızda Lefort I osteotomisi sonrası burun yumuşak dokusunda meydana gelecek istenmeyen değişikleri kontrol altına almak için kullanılan cinch sütürün etkinliğini değerlendirmek amaçlanmıştır. Çalışmamızda Lefort I osteotomisi sonrası maksiller ilerletme ve gömme yapılan vakaların hepsinde burunda genişleme olmuştur. Uygulanan cinch sütürün burundaki AG artışını kontrol altına almaya etkisi varken, SAG da meydana gelen genişlemeye etkisi olmadığı sonucu bulunmuştur.

Çeşitli çalışmalarda Lefort I osteotomisi sonrası AG'nin cinch sütüre uygulanan ve uygulanmayan hastalarda genişlemenin artığını gösteren veriler ortaya konmuştur., Mevcut çalışmamızda da iki gurupta artış olmuştur. AG mesafe cinch sütur uygulanan hastalarda ortalama %5.5 (1.88 mm) anlamlı artış, cinch sütur kullanılmayan kontrol hastalarında ise ortalama %6.8 (2.29 mm) anlamlı artış göstermiştir. Çalışma grubundaki hastalarda ameliyat öncesi ve sonrası AG değerleri arasında bulunan fark anlamlı olarak ilişkilendirilmemiştir yani cinch sütürün genişlemeyi engellemediğini göstermektedir.
Betts ve ark.14 yaptığı çalışmada SAG cinch sütür uygulan grupta %6.5 kontrol grubunda %10.6 artmıştır. Cinch sütürun etkinliğini değerlendiren diğer bir çalışmada SAG cinch sütüre kullanılan hastalarda %4.5 (1.5 mm) artış gösterirken kontrol gurubunda yapılan ölçümlerde artış %10.7 (3.6mm) bulunmuştur. Çalışmamızda SAG cinch sütur uygulanan hastalarda ortalama %8.2 (1.88 mm), cinch sütur kullanılmayan kontrol gurubu hastalarında ortalama %10.7 (2.57 mm) artış göstermiştir. SAG maksillanın hareketinden AG noktalarına göre genişleme oranı fazladır. Bunun sebebi SAG ölçüm noktalarının AG noktalarına göre maksiller kaideye daha yakın olmasıdır. Mevcut çalışmamızda SAG ölçümlerinde kontrol gurubunda meydana gelen genişleme cinch sütüre uygulananlara göre fazla ve istatiksel olarak anlamlıdır. Bu sonuç cinch sütürun etkisinin SAG artışını kontrol altına almada etkili olduğunu göstermektedir. Bunun sebebi cinch sütüre uygulama esnasında sütür ölçüm noktalarından geçirilerek gerildiği için subalar bölgeye direk etkisi olmaktadır.

Lefort I cerrahisi sonrası cinch sütür uygulanmayan hastalarda nazolabial açındaki değişikliğin anlamlı olmadığını raporlayan çalışmalar varken, nazolabial açının cerrahi sonrası anlamlı artığını gösteren çalışmalarda var. Mevcut çalışmada cinch sütürun genişlemeyi engelleyici etkisinin nazolabial açı değişikliğine etkisinin olup olmadığıda değerlendirilmek istendi. Ortognatik cerrahi işlem sonrası cinch sütur uygulanan grupta NLA ortalama 4,63º anlamlı olmayan azalma gösterirken, cinch sütür uygulanmayan grupta NLA ortalama 2,29º anlamlı olmayan artış göstermiştir. Esenlik ve ark. yaptığı maksillanın 6 mm ileri alındığı 3.5 mm gömme yapıldığı çalışmada NLA ortalama 2.4 mm azalmış. Nazolabial açı özellikle maksillanın gömme vektöründen azalarak etkilenmektedir. Yapılan analizde cinch sütüre uygulanan ve kontrol gurubunda NLA'nın gruplar arası arasında anlamlı ilişki görülmese de, yapılan hareketlerin etki yönlerinin bilinmesi hasta bilgilendirilmesi açısından önem arz etmektedir. Cinch sütur uygulanan bireylerde nazolabial açının artması beklenirken bizim çalışmamızda azalmıştır. Mevcut çalışmada maksiller hareket vektörü standardize edilmeye çalışılmış olsa da, maksiller hareketin yönü-miktarı, ortodontik tedavi, yumuşak doku iyileşmesi, deri-mukoza kalınlığı, etnik özellikler de NLA'yı etkilemektedir. Mevcut çalışmada nazolabial açıyı etkileyen diğer önemli faktör olan ANS traşlamasının yapıldığı vakalar dahil edilmemiştir.

Çalışmamız başladıktan sonraki bir yıl içinde kliniğimizde 42 ortognatik cerrahi ameliyat yapılmıştır. Yumuşak doku değişikliğine neden olan maksiller hareketin benzer olması için çalışma grubu, maksillanın ilerletildiği ve gömme yapıldığı vakalarla sınırlandırılmıştır. Bu durum hasta sayısının az olmasına neden olsa da güvenilir sonuç elde etmemizi sağlamıştır. Lefort I cerrahisi uygulanan hastalarda burun ve yumuşak doku değişimleri değerlendiren çalışmalarda hasta sayısı fazla olmakla beraber aynı vektörde hareketin buruna etkisini değerlendiren çalışmaya rastlanılmadı. Çalışmalar genel olarak Lefort I osteotomisi sonrası maksillanın çok yönlü hareketinin nazal dokuya etkisini değerlendirilmişti.,, Cinch sütürun etkisi direk olarak cerrahi operasyonda sütürlama sırasında görülmekle beraber nazal entübasyona bağlı burundan geçen tüp sağlıklı ölçüm yapmayı engellediği için cerrahi operasyon sırasında yapılan ölçüm çalışmaya dahil edilmemiştir.

SONUÇ

Çalışmamızda cinch sütürun sadece subalar bölgenin genişlemesini kontrol altına almakta klinik olarak anlamlı olduğu alar genişlemeyi engellemede etkinliği olmadığı sonucuna ulaşıldı. Cinch sütürun nasolabial açı değişimi üzerinde herhangi bir etkisi olmamıştır. Cinch sütüre kullanımına rağmen nasal kanatın genişleyeceği dikkate alınmalı ve hasta operasyon öncesi bilgilendirilmelidir.

KAYNAKLAR

1. Betts NJ, Edwards SP. Soft Tissue Changes Associated with Orthognathic Surgery. Milaro M. editor. Peterson's Principles of Oral and Maxillofacial Surgery; 2nd ed. Vol.2. Ontario, Canada: BC Decker Inc, 2004. Chapter 59.
2. Ryan FS, Barnard M, Cunningham SJ. What are orthognathic patients' expectations of treatment outcome—a qualitative study. J Oral Maxillofac Surg. 2012;70:2648-55.
3. Mani V, Panicker P, Shenoy A, George AL, Chacko T. Evaluation of Changes in the Alar Base Width Following Lefort 1 and AMO with Conventional Alar Cinch Suturing: A Photographic Study of 100 Cases. J Maxillofac Oral Surg. 2020;19(1):21-5.
4. Liu X, Zhu S, Hu J. Modified versus classic alar base sutures after LeFort I osteotomy: a systematic review. Oral Surg Oral Med Oral Pathol Oral Radiol. 2014 Jan;117(1):37-44
5. Bell WH, Proffit W. Esthetic effects of maxillary osteotomy. In: Bell WH, White RP, editors. Surgical correction of dentofacial deformities. Philadelphia: WB Saunder 1980

p. 368–70.
6. Cunningham SJ, Hunt NP, Feinmann C. Psychological aspects of orthognathic surgery: a review of the literature. Int J Adult Orthodon Orthognath Surg. 1995;10(3):159-72.
7. Schendel SA, Carlotti AE. Nasal considerations in orthognathic surgery. Am J Orthod Dentofacial Orthop. 1991;100:197-208.
8. Rauso R, Freda N, Curinga G, Del Pero C, Tartaro G. An Alternative Alar Cinch Suture. Eplasty 2010 Dec 20;10:e69.
9. Larrabee WF, Makielski KH, Henderson JL. Surgical anatomy of the face (2nd ed). Lippincott William and Wilkins. Philadelphia, 2004 pg 59.
10. O'Ryan F, Schendel S. Nasal anatomy and maxillary surgery. II: unfavorable nasolabial esthetics following the Le Fort I osteotomy. Int J Adult Orthodon Orthognath Surg. 1989;4:75-84
11. Millard RD. The alar base cinch in the flat, flaring nose. Plast Reconstr Surg. 1980;65:669-72.
12. Collins PC, Epker BN. The alar base cinch: a technique for prevention of alar base flaring secondary to maxillary surgery. Oral Surg Oral Med Oral Pathol. 1982;53:549-53.
13. Raithatha R, Naini FB, Patel S, Sherriff M, Witherow H. Longterm stability of limiting nasal alar base width changes with a cinch sütüre following Le Fort I osteotomy with submental intubation. Int J Oral Maxillofac Surg. 2017;46:1372-1379.
14. Betts NJ, Vig KW, Vig P, Spalding P, Fonseca RJ. Changes in the nasal and labial soft tissues after surgical repositioning of the maxilla. Int J Adult Orthodon Orthognath Surg 1993;8:7–23.
15. Mahsoub R, Naini FB, Patel S, Wertheim D, Witherow H. Nasolabial angle and nasal tip elevation changes in profile view following a Le Fort I osteotomy with or without the use of an alar base cinch sütüre: a long-term cohort study. Oral Surg Oral Med Oral Pathol Oral Radiol. 2020 Oct;130(4):379-86.
16. Betts NJ. Techniques to control nasal features. Atlas Oral Maxillofac Surg Clin North AM. 2000;8:53-69.
17. Guymon, M, Crosby DR, Wolford LM. The alar base cinch suture to control nasal width in maxillary osteotomies. Int J Adult Orthod Orthognath Surg 1988;3:89-95.
18. Stewart A, Edler RJ. Efficacy and stability of the alar base cinch suture. British Journal of Oral and Maxillofacial Surgery 2011;49:623–6.
19. Vasudavan S, Jayaratne YS, Padwa BL. Nasolabial soft tissue changes after Le Fort I advancement. J Oral Maxillofac Surg. 2012;70:e270-e277.
20. Metzler P, Geiger EJ, Chang CC, Sirisoontorn I, Steinbacher DM. Assessment of three-dimensional nasolabial response to Le Fort I advancement. J Plast Reconstr Aesthet Surg. 2014;67:756-63.
21. Westermark AH, Bystedt H, Von Konow L, Sallstrom KO. Nasolabial morphology after Le Fort I osteotomies. Effect of alar base sütüre. Int J Oral Maxillofac Surg. 1991;20:25-30.
22. Esenlik E, Kaya B, Gülsen A, Çukurluoğlu O, Özmen S, Yavuzer R. Evaluation of the nose profile after maxillary advancement with impaction surgeries. J Craniofac Surg. 2011 Nov;22(6):2072-9
23. Van Loon B, Verhamme L, Xi T, de Koning MJ, Bergé SJ, Maal TJ.Three-dimensional evaluation of the alar cinch suture after Le Fort I osteotomy. Int J Oral Maxillofac Surg. 2016 Oct;45(10):1309-14.
24. Muradin MS, Rosenberg A, Van der Bilt A, Stoelinga PJ, Koole R. The effect of alar cinch sutures and V–Y closure on soft tissue dynamics after Le Fort I intrusion osteotomies. J Craniomaxillofac Surg 2009;37:334–40.
25. Howley C, Ali N, Lee R, Cox S. Use of the alar base cinch suture in Le Fort I osteotomy: is it effective? Br J Oral Maxillofac Surg 2011;49:127–30.

EurAsian Journal of Oral and Maxillofacial Surgery
Official publication of AÇBİD (Association of Oral and Maxillofacial Surgery Society)

CASE REPORT

Application of TMJ Prosthesis After Multicystic Ameloblastoma Resection: A Case Report

Ömer ERDUR[1], Muhammed Sefer AKKOÇ, Research Assistant [2], **Ahmet AKTI[2], Gökhan GÜRSES[2], Adil ERSOY[2]**
[1]Selcuk University Medical Faculty, Department of Head and Neck Surgery, Konya
[2]Selcuk University Faculty of Dentistry Department of Oral and Maxillofacial Surgery, Konya

ABSTRACT

Objectives
Ameloblastoma treatment includes variable methods from conservative to radical. A radical treatment option needs to consider reconstructive procedures. Alloplastic joint prostheses which have been popular in recent years can be used. In this case report, we present a case who was rehabilitated with an alloplastic joint prosthesis after radical ameloblastoma treatment.

Case Description
A 64-year-old patient was referred to our clinic. In the radiological examination, a multicystic lesion extending from the corpus to the condyle of the right mandible was noticed. The biopsy procedure was applied under local anesthesia. The pathological examination result was ameloblastoma. Segmental resection of the relevant region and rehabilitation with a custom TMJ prosthesis in the region. The patient has been followed up for 5 months after the operation and is still being followed up.

Conclusion
After the TMJ prosthesis, we applied to our patient, our patient's speech and chewing function were largely preserved. In addition, there were no cosmetic problems. Although applying TMJ prostheses is more expensive than other radical treatments, it contributes greatly to patient morbidity.

Key words: ameloblastoma, reconstruction, temporomandibular prosthesis

INTRODUCTION

Ameloblastoma is an aggressive benign tumor that accounts for 1-3% of all tumors of the jaws and is four times more common in mandible[1]. It can cause perforation as well as expansion of the cortical bone but does not cause pain. Ameloblastomas have a high recurrence rate[1]. In 2005, the World Health Organization classified ameloblastomas as solid/multicystic ameloblastoma, unicystic ameloblastoma, peripheral (or extraosseous) ameloblastoma, and desmoplastic ameloblastoma[2].

Although the treatment of such a pathology can be done with conservative treatments such as enucleation, marsupialization, curettage and cryosurgery, the common treatment method is resection. After radical treatment of ameloblastoma, reconstructive procedures including bone grafts, distraction osteogenesis(DO), costochondral grafts, and other alternatives should be included in the surgical plan. The aim of this case report is to demonstrate the reconstruction of a solid/multicystic type large ameloblastoma case with a custom-made TMJ prosthesis treated with hemi-mandibulectomy[3].

CASE PRESENTATION

A 64-year-old female patient was referred to our clinic because of a lesion in the right ramus of the mandible. As a result of the radiological examination, in the right mandible; a multicystic lesion extending from the condyle to the corpus was observed. In the clinical examination, Although there was expansion in the condyle, mouth opening was at the lower limit of the normal range.. Right condyle area was sensitive to palpation. A sample was taken from the region under local anesthesia and sent to the pathological examination. As the pathology result was ameloblastoma, it was decided to remove the lesion by segmental resection. After the interviews with the patient, after the lesion was removed, it was decided to place a custom-made alloplastic TMJ prosthesis.

CBCT images of the patient were sent to a company supported by TUBITAK. A 3D model was created using tomography sections. After the osteotomy lines were determined, a TMJ prosthesis suitable for the region was produced. After we received the prosthesis, the patient was taken into operation. The patient was operated on under general anesthesia. Pre-

Corresponding Author: Muhammed Sefer AKKOÇ, Research Assistant
Address: Selcuk University Faculty of Dentistry Department of Oral and Maxillofacial Surgery, Alaeddin Keykubat Kampüsü, İsmet Paşa Cd.No:309, 42250 Selçuklu/Konya/Türkiye
Mobile: +90(505) 820 99 08
e-mail: msakkoc0603@gmail.com ORCID ID :0000-0002-2633-2121

op 2 g of cefazolin was given intravenously. The patient was intubated nasotracheal. Extra oral flaps were opened with preauricular and submandibular incisions. First, osteotomies were made from the regions determined on the model and the ameloblastoma was removed. The fossa component of the TMJ prosthesis was placed in the temporal bone and then fixed to the bone with screws. The ramus component of the prosthesis was passed under the opened flaps and the condyle component of the prosthesis was placed on the fossa component. Then it was fixed from the ramus part with the help of screws. During the operation, the patient's occlusion was controlled. Then, firstly, several flaps were removed from the temporal muscle and slid over the joint part of the prosthesis. The opened flaps were closed primarily.

The patient was discharged on the 3rd postoperative day. The patient's controls are carried out regularly. The patient has been followed for 5 months and is still being followed. In the control, the mouth opening of the patient was measured as 35 mm and there was no function loss.

DISCUSSION

Ameloblastoma is a benign lesion with aggressive features. It is observed more frequently in the mandible than in the maxilla[1]. The accepted and successful treatment is resection[4]. In cases of ameloblastoma extending to the condyle, such as in our case, reconstruction of the region following resection should also be considered. Because it is important to protect the patient's function and provide cosmetic needs as much as performing the treatment.

It can be grafted using autogenous bone graft for the reconstruction of the region. Only then, the operation time will be prolonged, the patient will feel discomfort in the donor area and it will be difficult to achieve occlusion[5,6]. Costochondral grafts are more preferred in growing patients[7]. In addition, 25% of costochondral graft use results in ankylosis[8]. In cases where reconstruction is performed using the distraction osteogenesis method, complications may develop depending on the apparatus used and the duration of treatment will be prolonged[9].

Alloplastic custom TMJ prostheses can be used not only for reconstruction after pathology treatment but also in cases such as degenerative joint diseases[10], ankylosis[11]and natal disorders[12].

Custom TMJ prostheses are a very good option for reconstruction after other tumor treatments such as ameloblastoma. As with autogenous treatments, the risk of complications is low and the effect on patient morbidity is limited. It can also be used by the patient quickly after the operation. However, its high cost can be challenging for patients. In addition, the production of custom made TMJ prostheses takes time. In addition, in the 20-year follow-up reports, pain felt in the jaw and improvement in jaw function in patients using custom-made TMJ prosthesis; An increase in the ability to eat solid food and an improvement in quality of life are reported[13].

CONCLUSION

The use of a custom TMJ prosthesis after TMJ resection in treatments for which resection is the accepted treatment, such as ameloblastoma, enables the patient to regain their functions quickly and effectively. In addition, a donor site is not required for autogenous grafting.

ACKNOWLEDGEMENT

Source of Finance
None declared.

Conflict of Interest
None declared.

Authorship of Contributions
Ömer Erdur, Muhammed Sefer Akkoç, Ahmet Aktı, Gökhan Gürses, Adil Ersoy

REFERENCES

1. Brad W. Neville, D. D. S., Douglas D. Damm, D. D. S., Allen DDS MSD, C. & Angela C. Chi, D. Oral and Maxillofacial Pathology. (Elsevier Health Sciences, 2015).
2. Milman, T., Ying, G.-S., Pan, W. & LiVolsi, V. Ameloblastoma: 25 Year Experience at a Single Institution. Head Neck Pathol. 10, 513–520 (2016).
3. Mercuri, L. G. Condyle replacement after tumor resection: comparison of individual prefabricated titanium implants and costochondral grafts. Oral Surgery, Oral Medicine, Oral Pathology, Oral Radiology, and Endodontology vol. 108 153–155 (2009).
4. Sham, E. et al. Mandibular ameloblastoma: clinical experience and literature review. ANZ J. Surg. 79, 739–744 (2009).
5. Hayden, R. E., Mullin, D. P. & Patel, A. K. Reconstruction of the segmental mandibular defect: current state of the art. Curr. Opin. Otolaryngol. Head Neck Surg. 20, 231–236 (2012).
6. Carlson, E. R. Disarticulation resections of the mandible: A prospective review of 16 cases. J. Oral Maxillofac. Surg. 60, 176–181 (2002).
7. Fernandes, R., Fattahi, T. & Steinberg, B. Costochondral rib grafts in mandibular reconstruction. Atlas Oral Maxillofac. Surg. Clin. North Am. 14, 179–183 (2006).
8. Medra, A. M. M. Follow up of mandibular costochondral grafts after release of ankylosis of the temporomandibular joints. Br. J. Oral Maxillofac. Surg. 43, 118–122 (2005).
9. Quinn, P. D. & Granquist, E. J. Atlas of Temporomandibular Joint Surgery. (John Wiley & Sons, 2015).
10. Kashi, A., Saha, S. & Christensen, R. W. Temporomandibular joint disorders: artificial joint replacements and future research needs. J. Long Term Eff. Med. Implants 16, 459–474 (2006).
11. Mercuri, L. G. Alloplastic temporomandibular joint reconstruction. Oral Surg. Oral Med. Oral Pathol. Oral Radiol. Endod. 85, 631–637 (1998).
12. Kryshtalskyj, B. Total prosthetic joint replacement for the end-stage of TMJ disease. Ont. Dent. 67, 25, 27–9 (1990).
13. Wolford, L. M., Mercuri, L. G., Schneiderman, E. D., Movahed, R. & Allen, W. Twenty-Year Follow-up Study on a Patient-Fitted Temporomandibular Joint Prosthesis: The Techmedica/TMJ Concepts Device. Journal of Oral and Maxillofacial Surgery vol. 73 952–960 (2015).

EurAsian Journal of Oral and Maxillofacial Surgery
Official publication of AÇBİD (Association of Oral and Maxillofacial Surgery Society)

CASE REPORT

Giant Cell Angiofibroma: A Rare Tumour in the Oral Cavity

Issa Al AZRI, Resident[1], **Ahmed Al HASHMI,** Consultant in Oral and Maxillofacial Surgery [2], **Hunaina Al KINDI,** Consultant in Histopathology[3], **Mina GEORGE,** Histopathologist [3], **Kaouther BACCOUCHE,** Histopathologist [3]
[1]Oral and Maxillofacial Surgery Residency Program, Oman Medical Speciality Board, Muscat, Oman
[2]Oral and Maxillofacial Surgery Department, Al Nahdha Hospital, Muscat, Oman
[3]Department of Histopathology, Khoula hospital, Muscat, Oman

ABSTRACT

Giant cell angiofibroma (GCA) was first described as a distinctive orbital soft-tissue tumour. It is now recognised that this rare tumour can present in other anatomical regions including the oral cavity. Here, we report a case of a 26-year-old male with a primary complaint of a painless solitary swelling on the right buccal mucosa. The lesion was surgically excised and a diagnosis of GCA was made based on light microscopy and immunohistochemical (IHC) studies. At present, local excision with long-term follow-up seems to be the most appropriate management modality. To the best of our knowledge, only four cases of GCA arising in the oral cavity were reported in the literature.

Keywords: Giant cell angiofibroma; giant cell fibroblastoma;solitary fibrous tumor; immunohistochemistry; case report; Oman

INTRODUCTION

Giant cell angiofibroma is a benign mesenchymal soft tissue tumour that commonly occurs in the orbital region.[1] However, it is recognised that this lesion can also occur in other locations including oral cavity. There are only four cases of GCA within the oral cavity reported in the literature.[2,3,4,5] In this paper, we present a case of GCA affecting buccal mucosa describing clinical, histopathological and IHC features.

CASE REPORT

A 26-year old male reported to the maxillofacial clinic with chief complaint of a painless swelling on the right side of the lower jaw. The swelling has been present since the past three years with slowly progressive increase in size. Clinical examination revealed an extra-oral firm swelling on the right side of the lower jaw. Intraorally there was a raised, painless, sessile, nodular lump measuring 25 mm and located in the right buccal mucosa. Our clinical diagnosis was a benign neoplasm such as lipoma. The lesion was surgically excised via intraoral approach and the specimen was submitted for histopathological examination. (Figure 1, 2)

Figure 1. Surgical exposure of the lesion.

Corresponding Author: Issa Al Azri, Resident
Address: Kutahya Health Science University, School of Dentistry, Department of Oral and Maxillafacial Surgery
Istıklal Neighborhood, Lala Huseyin Pasa street, No: 43100, Kütahya
Mobile: 977973304
e-mail: issa.a18@resident.omsb.org

Figure 2. Excised specimen.

Pathological findings

On gross examination, the specimen was ovoid in shape and red in color showing a well encapsulated lesion. Microscopic examination revealed circumscribed cellular spindle cells with interspersed staghorn vessels. (Figure 3) The neoplastic cells were spindly with a storiform architecture. They were medium in size, oval with vesicular nuclei. In addition, there was occasional multinucleate giant cells, a sprinkling of lymphocytes and scattered collections of foamy macrophages. Immunohistochemistry (IHC) showed positivity of the neoplastic cells for Vimentin, SMA, CD34 and CD99 but negative for other markers. After 4 months of follow-up no recurrence was observed.

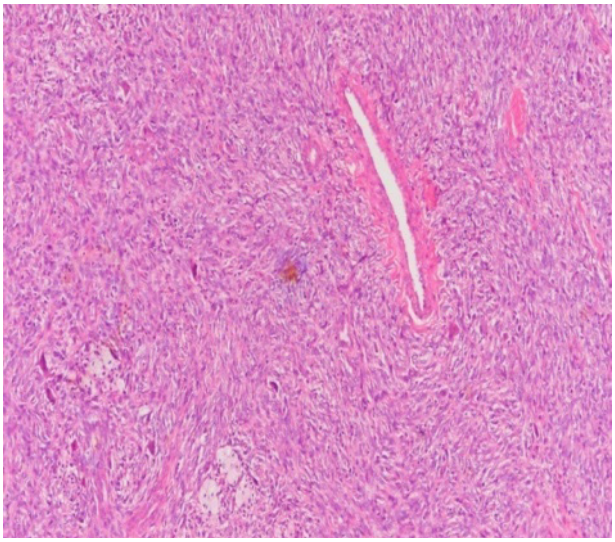

Figure 3: A. Photomicrograph showing neoplastic spindle cells with a storiform architecture with interspersed staghorn vessels (H&E X10 magnification).

DISCUSSION

GCA is a benign tumour that was first described in 1995 by Dei Tos et al.[1] as a distinctive orbital tumor occurring exclusively in male adults. However, this tumour can also present in other locations, and many cases reported in extra-orbital sites.[6,7,8] Only four cases occurring in the oral cavity reported in the literature, three arising in the buccal mucosa, and other affecting the gingiva.[2,3,4,5] The mean age of affected patients was 53. GCA has a potential for local recurrence, especially after incomplete resection but has no metastatic spread.[1,2,3,4,5,6,,7,8]

The typical histological picture of GCA reveals a richly vascularized, patternless spindle-cell proliferation with pseudovascular spaces. Multinucleated giant cells of the floret type occur throughout the lesion and line the pseudovascular spaces.[1,2] In fact, Dei Tos et al. described the histologic features of GCA as intermediate between giant cell fibroblastoma (GCF) and solitary fibrous tumor (SFT).

GCF is an uncommon, benign tumor of soft tissue most often presents in early childhood. GCF and GCA are closely related tumors, both show IHC staining for vimentin, and CD34.[8] SFT is a rare soft tissue neoplasm, which was originally described in the pleura.[9] Since their initial description as a pleural tumour, SFTs have been reported at a wide range of anatomic sites including oral cavity.[10] The tumour cells are positive to vimentin and CD34 making it difficult to be differentiated from GCA.

In, addition, many other soft tissue tumors share the same histological and IHC features of GCA. These lesions include dermatofibrosarcoma protuberans (DFSP), pleomorphic hyalinizing angiectatic tumour (PHAT) of soft parts, multinucleate cell angiohistiocytoma (MCAH), benign fibrous histiocytoma (BFH), and angiomyolipoma (AML).[4]

CONCLUSION

We report the fifth case of GCA arising in the oral cavity. At this time, local excision with long-term follow-up seems to be the most appropriate management option with possibility of recurrence especially if left incompletely resected. It is essential to be aware of this tumour in order to avoid misdiagnosis with others fibrous tumours.

ACKNOWLEDGEMENT

We thank Dr. Abdul Rahman Al Azri, oral pathologist and Dr Said Al Rashdi, OMFS specialist for their input during surgical procedure, data interpretation and manuscript preparation.

REFERENCES

1. Dei TA, Seregard S, Calonje E, Chan JK, Fletcher CD. Giant cell angiofibroma. A distinctive orbital tumor in adults. Am J SurgPathol 1995;19:1286-93.
2. Kintarak S, Natiella J, Aguirre A, Brooks J. Giant cell angiofibroma of the buccal mucosa. Oral Surg Oral Med Oral Pathol Oral Radiol. Endod. 1999 Dec;88(6):707-13.
3. Rousseau A, Perez-Ordonez B, Jordan RC. Giant cell angiofibroma of the oral cavity: report of a new location for a rare tumor. Oral Surg Oral Med Oral Pathol Oral RadiolEndod. 1999 Nov;88(5):581-5.
4. de Andrade CR, Lopes MA, de Almeida OP, León JE, Mistro F, Kignel S. Giant cell angiofibroma of the oral cavity: a case report and review of the literature. Med Oral Patol Oral Cir Bucal. 2008; 13:E540–E543.
5. Ajura Abdul Jalil, Lau Shin Hin. Oral giant cell angiofibroma: A case report. Oral Surg Oral Med Oral Pathol Oral Radiol.2015 March: E158.
6. Husek K, Veselý K. Extraorbital giant cell angiofibroma. CeskPatol. 2002 Jul;38(3):117-20. 6. Qian YW, Malliah R, Lee HJ, Das K,Mirani N, Hameed M. A t(12;17) in an extraorbital giant cell angiofibroma. Cancer Genet Cytogenet. 2006 Mar;165(2):157-60.
7. Thomas R, Banerjee SS, Eyden BP, Shanks JH, Bisset DL, Hunt R, et al. A study of four cases of extra-orbital giant cell angiofibromawith documentation of some unusual features. Histopathology. 2001 Oct;39(4):390-6.
8. .Fletcher CD. Giant cell fibroblastoma of soft tissue: a clinicopathological and immunohistochemical study. Histopathology 1988;13:499-508.
9. Dalton WT, Zolliker AS, McCaughey WTE, Jacques J, Kanerstein M. Localized primary tumors of the pleura. Cancer 1979;44:1465-75.
10. Goodlad JR, Fletcher CD. Solitary fibrous tumour arising at unusual sites: analysis of a series. Histopathology 1991;19:515- 22.

EurAsian Journal of Oral and Maxillofacial Surgery
Official publication of AÇBİD (Association of Oral and Maxillofacial Surgery Society)

CASE REPORT

Maxillary Sinus Barotrauma with Infraorbital Nerve Paresthesia After Scuba Diving: A Case Report

Mehmet Zahit BAŞ, Assist. Prof., **Semiha Seda ŞAHİN,** PhD
Department of Oral and Maxillofacial Surgery, Faculty of Dentistry, University of Health Sciences, Istanbul, Türkiye

ABSTRACT

Barotrauma is defined as pressure-induced tissue injury. Paranasal sinus barotrauma of descent (sinus squeeze) is the result of negative pressure in the sinus cavity. Upper respiratory tract infections, nasosinusal pathologies, inappropriate diving techniques and forceful Valsalva's manoeuvres are common predisposing factor for paranasal sinus barotrauma. The management of paranasal sinus barotrauma includes: Prevention with vasoconstrictor drops, hyperbaric oxygen therapy and surgery. The aim of this case report is to evaluate diagnosis and treatment options of maxillary sinus barotrauma that is a very rare condition in dentistry.

Keywords: barotrauma, maxillary sinus, oral surgery

INTRODUCTION

Paranasal sinus barotrauma or aeorosinusitis is defined as tissue damage due to sudden pressure changes. It results from an inability to balance pressure in the sinuses, which is caused by the rapid change in barometric pressure difference between the intrasinusal air and the surrounding atmosphere[1,2].

Sinus baratrauma due to negative air pressure during descent while diving is termed 'sinus squeeze' which causes, oedema, mucosal congestion and haemorrhage within the cavity, accompanied by immediate facial pain[2].

Paranasal sinus barotrauma is the result of negative pressure in the sinus cavity and it is the most common type of barotrauma following middle ear barotrauma in diving related problems among SCUBA divers[3,4]. Maxillary sinus barotrauma is the most common type of paranasal sinus barotrauma[5].

In this case, we present the treatment of left maxillary sinus baratrauma accompanied by infraorbital nerve involvement after scuba diving.

CASE REPORT

A 25 years old systematically healthy male patient was applied to University of Health Sciences, Oral and Maxillofacial Surgery Department with complaints of pain in the left maxillary sinus area and infraorbital nerve paresthesia after scuba diving. The final diagnosis of paranasal sinus barotrauma is made after clinical and radiographic examination (panoramic radiograph and magnetic resonance imaging (MRI). Congestion filling the left maxillary sinus was observed on MRI. (Fig.1) The patient had complaints of numbness and tingling sensation in the left upper lip, cheek and lateral of the nose. This was due to compression on the infraorbital nerve.

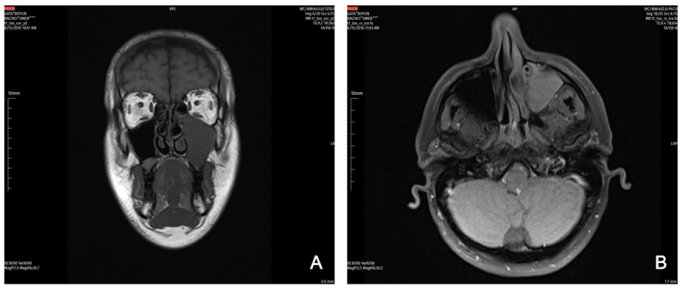

Fig. 1. Pre-operative magnetic resonance imaging (MRI).

A. Coronal plane. Congestion in the left maxillary sinus (arrow).
B. Axial plane. Congestion in the left maxillary sinus (arrow).

His complaints didn't decrease with conservative treatment. Therefore, Caldwell-Luc operation was applied to the patient under local anesthesia and the left maxillary sinus was treated surgically. In the surgical treatment, sinus drainage was

Corresponding Author: Mehmet Zahit Baş, Assist. Prof.
Address : Sultan Abdulhamid Han Research Hospital, University of Health Sciences, Tıbbiye Street, Number: 38 34668 Uskudar/İstanbul
Mobile : +90 (533) 039 74 48
e-mail : mehmet_bass@windowslive.com ORCID: 0000-0003-0892-4067

performed with the Caldwell Luc procedure. (Fig.2) After the procedure oral antibiotics, analgesics and nasal decongestants were prescribed. In addition post-operative sinus precautions were explained to the patient and he was followed up for 3 years and no complaints received (Fig. 3)

Fig. 2. Caldwell-Luc surgery in the left maxillary sinus.

Fig. 3. Post-operative controls after Caldwell-Luc surgery.
A. First year after the surgery.
B. Second year after the surgery.
C. Third year after the surgery.

DISCUSSION

Barotrauma is the damage caused by the direct effect of pressure on the tissues. Generally, recreational scuba diving takes place at depths of 60 to 130 ft (~18-40 m), where a pressure level of 3 to 5 atm is equivalent to absolute pressure.

The sinus ostia must remain open throughout the dive to equalize the ambient pressure through the nose. If it fails to equalize the pressure during descent, a vacuum effect occurs within the sinus and mucosal congestions, eodema, hemorrhagic bullae and free blood may be seen[6].

In our case, maxillary sinus baratrauma was observed in the patient who was afraid of diving at a depth of 5 meters and made a rapid ascent, didn't equalize the pressure.

Maxillary sinus is one of the most common site for paranasal sinus barotrauma. In addition the frontal, ethmoid, and sphenoid sinuses may also be affected as well as more than one sinuse can be affected in one patient. Maxillary sinus squeeze causes pain that can be seem as caused by the teeth of the upper jaw. The maxillary division of the fifth cranial nerve can be damaged by excessive pressure as it passes through the sinus covered with the mucous membrane. This can cause a loss of sensation over unilateral side of the upper face[7,8,9].

In the literature, cases of paraesthesia of the nerve infraorbital nerve related to maxillary sinus barotrauma have been reported[7,8,9]. In this case, in accordance with these cases, reflected pain in the maxillary teeth caused by the pressure on the posterior superior alveolar branch, and numbness and tingling in the lips and cheeks due to the presthesis of the infraorbital nerve were observed.

Although radiological reports of sinus barotraumas are scarce; they can be detected with plain films, computed tomography and magnetic resonance imaging[2].

Recurrent sinus barotrauma should be differentiated from chronic sinusitis. Patients with evidence of chronic sinusitis should be treated with appropriate medical therapy[10]. Sinus surgery is recommended if radiological signs of the disease persist. In addition, patients who have clinical and radiological signs of sinusitis are always at risk for barotrauma while scuba diving due to ostial insufficiency[6].

Primarily, medical treatment was chosen, and when it was unsuccessful, patient was treated surgically. After the surgery, the patient's current pain and paresthesia complaints disappeared and no symptoms were observed except chronic sinusitis symptoms during the follow-up period.

ACKNOWLEDGEMENT

Source of Finance
The study needs no financial support.

Conflict of Interest
The authors have no conflict of interest to declare.

Authorship of Contributions
Mehmet Zahit Baş and Semiha Seda Şahin designed the study and gathered the data. Mehmet Zahit Baş analyzed the data. Mehmet Zahit Baş and Semiha Seda Şahin wrote the majority of draft.

REFERENCES

1. R V, B van H, I C, J M. Frontal Sinus Barotrauma. J Belgian Soc Radiol. 2016;100(1). doi:10.5334/JBR-BTR.908
2. C B, A G. Sphenoid sinus barotrauma after free diving. Am J Otolaryngol. 2011;32(2):159-161. doi:10.1016/J.AMJOTO.2009.10.005
3. P MM, S DA, G JL, M WL E. Underwater medicine: otolaryngologic considerations of the skin and scuba diver. In: Reuter SH, ed. Otolaryngology. WB Saunders; 1991:3231–57.
4. LM N. Otolaryngology and sport scuba diving. Update and guidelines. Ann Otol Rhinol Laryngol Suppl. 1985;115:1-12. Accessed September 6, 2021. https://pubmed.ncbi.nlm.nih.gov/2857546/
5. P F, B M, C E. Sinus barotrauma in divers. Ann Otol Rhinol Laryngol. 1976;85(1 Pt 1):61-64. doi:10.1177/000348947608500110
6. GD B, GJ P. Barotrauma of the ears and sinuses after scuba diving. Eur Arch Otorhinolaryngol. 2001;258(4):159-163. doi:10.1007/S004050100334
7. B FK, B AA. Infraorbital hypesthesia after maxillary sinus barotrauma. Undersea Hyperb Med. 1999;26(4):257-259.
8. G LM. Maxillary sinus barotrauma - Case report and review. Aviat Sp Environ Med. 1985;56(8):796-802.
9. AW M, DJ S, TJ F, RT C. Maxillary sinus barotrauma with fifth cranial nerve involvement. J Laryngol Otol. 1991;105(3):217-219. doi:10.1017/S0022215100115415
10. T S, I B, T B, N C, PK P, C K. Medical and surgical treatment in divers with chronic rhinosinusitis and paranasal sinus barotrauma. Eur Arch Otorhinolaryngol. 2012;269(3):853-860. doi:10.1007/S00405-011-1742-4